

ORIGINAL ARTICLE

PEER REVIEWED | PROVISIONAL PDF

# Fistulectomy and primary repair of wound and anal sphincter by Lasheen's sutures for high perianal fistula

Ahmed E. Lasheen, Khaled Safwat, Basem Sieda, Mostafa Baiomy, Ashraf Ismaeil, Zaki Allam, Wael Awad

## ABSTRACT

**Aims:** Several techniques have been described for the management of fistula-in-ano. Ideal surgical treatment for anal fistula should aim to eradicate sepsis and promote healing of the tract, whilst preserving the sphincters and the mechanism of continence. This study offers our technique to achieve this goal. **Methods:** Between January 2013 and December 2014, 77 patients with high perianal fistula were treated by fistulectomy and repair of the anal wound and sphincter by multiple Lasheen's sutures. The clinical outcome was assessed in terms of continence and recurrence for follow-up period (ranged from 3 to 24 months). **Results:** The anorectal wounds were healed within 4 to 6 weeks. Early complications included superficial wound infection in 27 patients (35%), urine retention in 21 patients (27%), transient incontinence in 41 patients (53%) for flatus for period ranged from 2 to 3 weeks. No permanent incontinence, no deep infection, or abscess formation, or recurrence was recorded during the follow-up period. **Conclusion:** Our technique is easy, novel, and associated with good results for high perianal fistula management.

**Keywords:** Anal sphincter, Fistulectomy, Lasheen's suture, Perianal fistula, Wound

## How to cite this article

Lasheen AE, Safwat K, Sieda B, Baiomy M, Ismaeil A, Allam Z, Awad W. Fistulectomy and primary repair of wound and anal sphincter by Lasheen's sutures for high perianal fistula. *Edorium J Surg* 2015;2:16–20.

Article ID: 100007S05AL2015

\*\*\*\*\*

doi:10.5348/S05-2015-7-OA-5

## INTRODUCTION

Fistula-in-ano is a common condition associated with appreciable inconvenience and morbidity to the patients. Centuries have passed but the basic principles of management of anorectal sepsis remained the same which revolves around resolution of anorectal sepsis and treatment of fistula without hampering continence [1]. Conventional classification and treatment depends on the level of the internal opening and extent of involvement of the external sphincter by the fistulous tract [2, 3]. For the simple and most distal fistula, conventional surgical treatment such as lay – open of the fistula tract as a complete transaction of the tissue between the fistula tract and anoderm is very effective with a success rate of up to 100% [4]. High fistulas have been treated by a number of techniques (fistulotomy, rerouting fistula tracts, loose and tight seton sutures) with variable results in terms of recurrence and a disturbance [5, 6]. Core fistulectomy and closure of internal opening techniques have been reported with some difficulties [7, 8]. In this article, using fistulectomy and repair of anal sphincter by Lasheen's sutures in high perianal fistula treatment, surgical technique and the clinical results are discussed.

Ahmed E. Lasheen<sup>1</sup>, Khaled Safwat<sup>1</sup>, Basem Sieda<sup>1</sup>, Mostafa Baiomy<sup>1</sup>, Ashraf Ismaeil<sup>1</sup>, Zaki Allam<sup>1</sup>, Wael Awad<sup>1</sup>

**Affiliations:** <sup>1</sup>General, laparoscopic Department, Zagazig University Hospital, Zagazig University, 44519, Egypt.

**Corresponding Author:** Ahmed E. Lasheen, Postal address: General Surgery Department, Faculty of Medicine, Zagazig University 44519, Egypt; Ph: 0020552343035; Email: lasheenahmed@yahoo.com

Received: 11 June 2015

Accepted: 03 July 2015

Published: 07 September 2015

## MATERIALS AND METHODS

This research was discussed and approved from the ethical Committee of Zagazig University in December 2012. All information about this study was discussed with all patients, and all patients gave writing consent for inclusion of their data in this study. Between January 2013 and December 2014, the study population consisted of 77 patients (50 male and 27 female) suffering from high perianal fistulas according to the criteria of Parks et al., with a median age of 45 years (18–62 years) [9]. Five patients (9%) had previously undergone one or more repair attempts before referral for this technique. Before operation every patient underwent a digital examination, transrectal endosonography, and fistulography. All patients were continent. All patients underwent a mechanical bowel preparation, and received systemic antibiotic 12 hours preoperatively and 7 days postoperatively. Under general or spinal anesthesia, the patient was placed in the lithotomy position. The fistulous tracts, and external and internal openings were located. Complete and close fistulectomy was done. Then, repair of anal wound and sphincter was done by multiple double incomplete circular sutures (Lasheen's suture) passed under the wound floor using Vicryl No. 2/0 on round needle. The needle with Vicryl passed from one edge of wound through the sphincter muscle, under the wound floor until reaching to another wound edge. Then, returned in opposite direction to the starting point by same manner with distance between two limbs of suture about 1 to 1.5 cm. Also, the distance between each suture and another was about 2 cm. Now, one suture becomes complete and two suture limbs were holed by tissue forceps Figure 1 and Figure 2. Multiple sutures were used, where were tied them making the wound and muscles edges become close to each other Figure 2. So, primary repair of anal sphincter and wound was achieved by our sutures without forming closed space of wound, which allows for free drainage of the wound through its length and depth. Local wound care was continuous cleaning of wound and application of topical ointment contains local anesthetic and promotes healing agents. The follow-up period was ranged from 3 to 24 months (mean-20 months) for this patients group.

## RESULTS

Our technique was done under general anesthesia in 57 patients and 20 patients under spinal anesthesia. The two limbs of each suture must be passed at big distance (3–5 cm) from both edges of anal sphincter muscles and just under the wound floor (0.5 cm). The sutures were tied only after finishing of putting all needed sutures. This technique is easier with using long (5–7 cm), curved and rounded needle. All anorectal wounds and sphincter were healed within 4–6 weeks. Early complications included superficial infection in 27 (35%) patients, urine retention

21 (27%) patients, transient incontinence in 41 (53%) patients for flatus only for period ranged from 2–3 weeks. No permanent incontinence, or deep infection or abscess formation, or recurrence were recorded in this patients group during the period of follow-up.

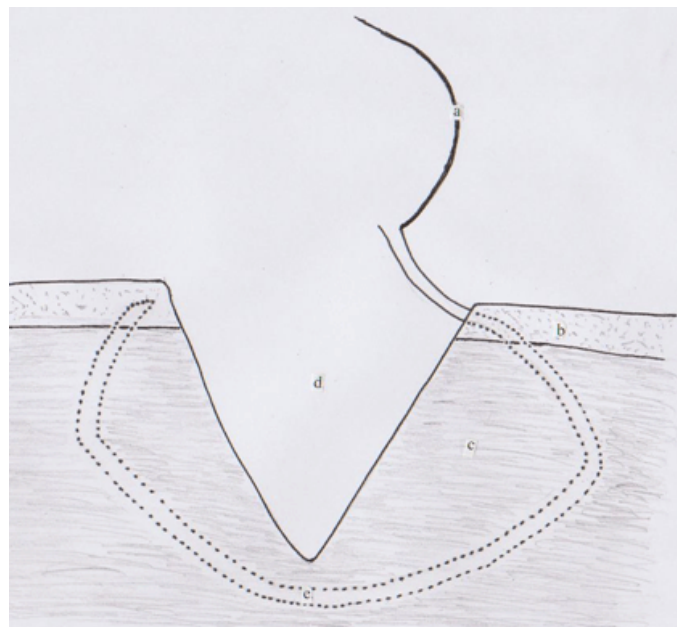


Figure 1: (a) Needle with Vicryl No. 0, (b) Subcutaneous and submucosa layer, (c) Sphincter muscle layer, (d) Anal wound, (e) Incomplete double circular berried stitch. The needle with Vicryl was passed from one wound side under the superficial layer, through the muscle sphincter, under the wound floor until reaching the superficial layer from other wound side, and return in opposite direction until coming from near the first step.




Figure 2 The incomplete double circular berried suture (Lasheen's suture) was tied putting the two sphincter ends close to each other without forming closed space of the wound allowing for free drainage of anal wound. This leads to good wound healing without fecal diversion.



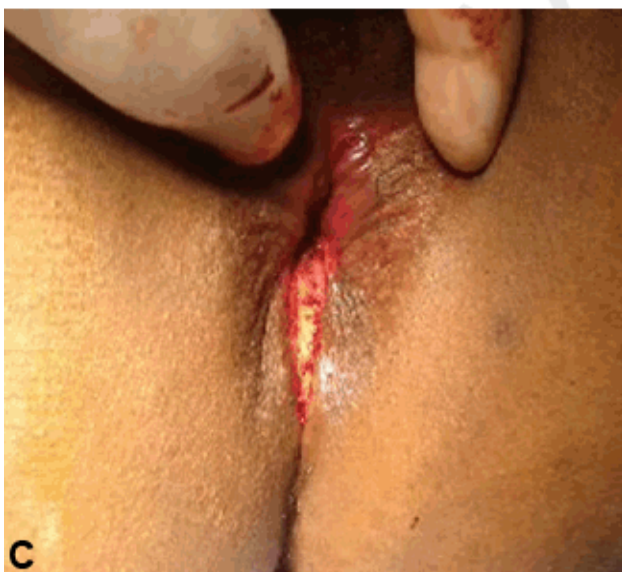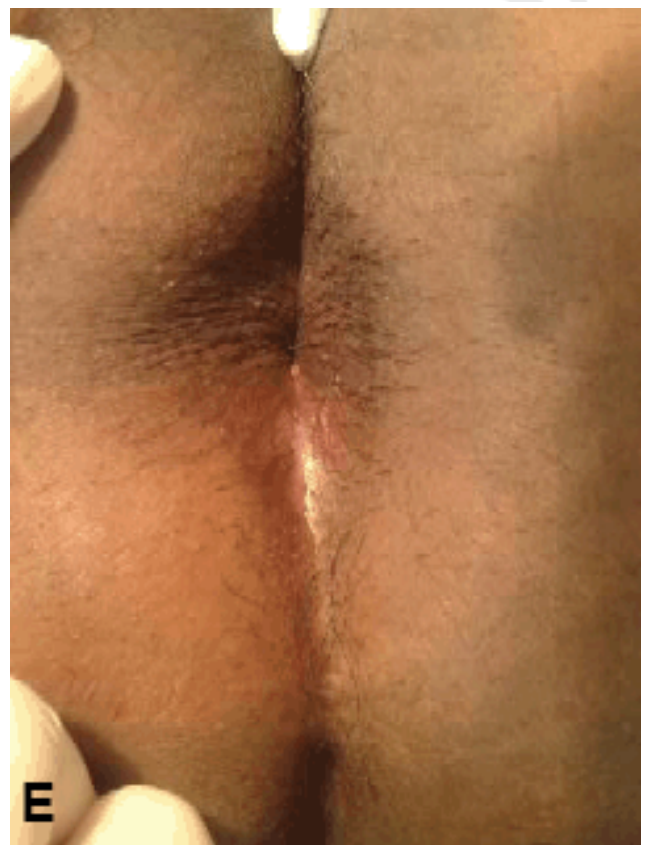
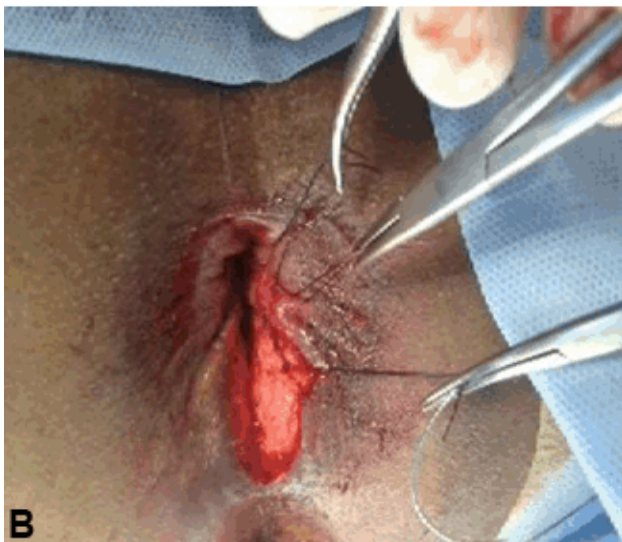

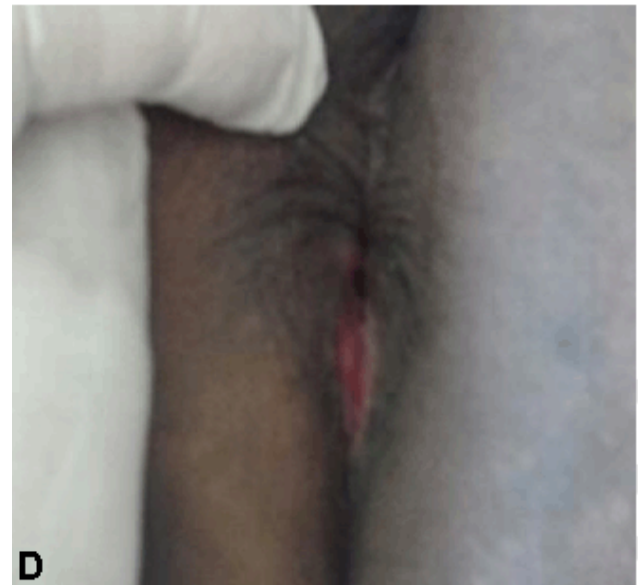
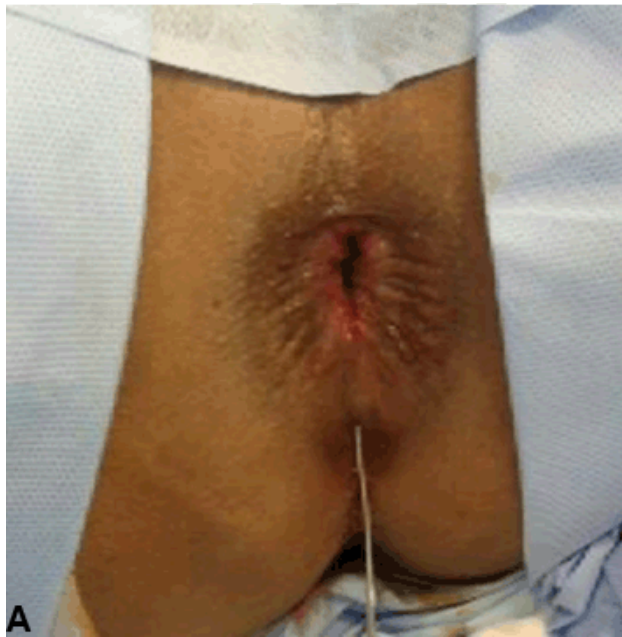Figure 3: (A): One patient was suffering high perianal fistula (probe inside the tract through external opening), patient under general anesthesia and at lithotomy position, (B) Core fistulectomy after division of anal sphincter superficial to fistula tract was done. Then, three incomplete double circular berried sutures (Lasheen's suture) were putting and holding by tissue forceps, (C) All sutures were tied putting the two sphincter ends close to each other without forming closed space of the wound allowing for free drainage of anal wound, (D) Same patient after two weeks of operation, the anal sphincter was well healed and there is small raw area, (E) Figure 3e : Same patient after four weeks, showed complete healing for anal sphincter and wound, leaving the anus normal in function and morphology.

## DISCUSSION

\*\*\*\*\*

The ideal surgical treatment of anal fistula should eradicate sepsis and promote healing of the tract, whilst preserving the sphincters and the mechanism of continence. For the low perianal fistula, conventional surgical treatment such as lay-open of the fistula tract is very effective method [4]. However, if applied to high perianal fistulas, this technique often leads to incontinence and perianal scarring which may further compromise the functional outcome [10, 11]. Surgical pathology of perianal fistula is the presence of internal opening at anorectal area, presence of fistula tract which may be partial epithelized, and presence of sepsis collection. In high perianal fistula the tract passes through the upper two third of external sphincter [12]. The traditional method of laying open the fistula tract is undoubtedly successful in achieving eradication of the fistula, but leads to fecal incontinence in high fistula type [13]. There are various treatment options for treating high perianal fistula, all depend on core fistulectomy, closure the internal opening and leaving the external opening for drainage [8]. There are many options for closure of internal opening as endorectal flap [14], fistula wall flap [8], fibrin glue [15], fistula plug [16], stem cells [13]. Many authors using these techniques reported variable recurrence rates ranging from zero to 30% and 8% fecal incontinence [17–19]. I think, this is due to difficulties to complete closure of internal fistula opening or difficult to complete excision of tract leading to fistula recurrence or more excision of muscle sphincter around the fistula tract leading to fecal incontinence. Seton are other optional treatment for high perianal fistula, the seton placement has been advocated either loose, to control infection, or cutting through the sphincter muscle gradually or as bridge between two separate partial fistulotomies [20, 21]. Incontinence still continues to complicate seton treatment, through they are projected as sphincter saving procedures and the reasons for this could be hard gutter shaped scars, loss of anal sensations. The use of setons in modern day practices is restricted [1]. In our technique, the core fistulectomy was done close and complete after division of muscle of sphincter superficial to tract from external to internal openings. Then, by Lasheen's sutures primary repair of sphincter and wound was done putting the both ends of sphincter close to each other, without producing closed space. This is allowing to free drainage of all length and depth of wound through all stages of healing. So, healing of anal wound and sphincter was happen well and without any gutter formation or keyhole deformity

## CONCLUSION

Our technique, offers novel method easy, associated with good results in form no recurrence and no permanent incontinence in treatment of high perianal fistula.

## Author Contributions

Ahmed E. Lasheen – Substantial contributions to conception and design, Acquisition of data, Analysis and interpretation of data, Drafting the article, Revising it critically for important intellectual content, Final approval of the version to be published

Khaled Safwat – Analysis and interpretation of data, Revising it critically for important intellectual content, Final approval of the version to be published

Basem Sieda – Analysis and interpretation of data, Revising it critically for important intellectual content, Final approval of the version to be published

Mostafa Baiomy – Analysis and interpretation of data, Revising it critically for important intellectual content, Final approval of the version to be published

Ashraf Ismaeil – Analysis and interpretation of data, Revising it critically for important intellectual content, Final approval of the version to be published

Zaki Allam – Analysis and interpretation of data, Revising it critically for important intellectual content, Final approval of the version to be published

Wael Awad – Analysis and interpretation of data, Revising it critically for important intellectual content, Final approval of the version to be published

## Guarantor

The corresponding author is the guarantor of submission.

## Conflict of Interest

Authors declare no conflict of interest.

## Copyright

© 2015 Ahmed E. Lasheen et al. This article is distributed under the terms of Creative Commons Attribution License which permits unrestricted use, distribution and reproduction in any medium provided the original author(s) and original publisher are properly credited. Please see the copyright policy on the journal website for more information.

## REFERENCES

1. Akhtar M. Fistula in Ano - An Overview. JIMSA 2012;25(1):53–5.
2. Lewis A. Excision of fistula in ano. Int J Colorectal Dis 1986 Oct;1(4):265–7.
3. Kodner IJ, Mazor A, Shemesh EI, Fry RD, Fleshman JW, Birnbaum EH. Endorectal advancement flap repair of rectovaginal and other complicated anorectal fistulas. Surgery 1993 Oct;114(4):682–9; discussion 689–90.
4. Westerterp M, Volkers NA, Poolman RW, van Tets WF. Anal fistulotomy between Skyla and Charybdis. Colorectal Dis 2003 Nov;5(6):549–51.
5. Williams JG, MacLeod CA, Rothenberger DA, Goldberg SM. Seton treatment of high anal fistulae. Br J Surg 1991 Oct;78(10):1159–61.

6. Mann CV, Clifton MA. Re-routing of the track for the treatment of high anal and anorectal fistulae. *Br J Surg* 1985 Feb;72(2):134–7.
7. Ortíz H, Marzo J. Endorectal flap advancement repair and fistulectomy for high trans-sphincteric and suprasphincteric fistulas. *Br J Surg* 2000 Dec;87(12):1680–3.
8. Lasheen AE. Partial fistulectomy and fistular wall flap for the treatment of high perianal fistulas. *Surg Today* 2004;34(11):977–80.
9. Parks AG, Gordon PH, Hardcastle JD. A classification of fistula-in-ano. *Br J Surg* 1976 Jan;63(1):1–12.
10. Marks CG, Ritchie JK. Anal fistulas at St Mark's Hospital. *Br J Surg* 1977 Feb;64(2):84–91.
11. Sainio P, Husa A. A prospective manometric study of the effect of anal fistula surgery on anorectal function. *Acta Chir Scand* 1985;151(3):279–88.
12. Whiteford MH, Kilkenny J 3rd, Hyman N, et al. Practice parameters for the treatment of perianal abscess and fistula-in-ano (revised). *Dis Colon Rectum* 2005 Jul;48(7):1337–42.
13. Limura E, Giordano P. Modern management of anal fistula. *World J Gastroenterol* 2015 Jan 7;21(1):12–20.
14. Ghahramani L, Bananzadeh AM, Izadpanah A, Hosseini SV. Late results of endorectal flap in management of high type perianal fistula. *Middle East J Dig Dis* 2012 Jul;4(3):163–7.
15. Mishra A, Shah S, Nar AS, Bawa A. The role of fibrin glue in the treatment of high and low fistulas in ano. *J Clin Diagn Res* 2013 May;7(5):876–9.
16. Fox A, Tietze PH, Ramakrishnan K. Anorectal conditions: anal fissure and anorectal fistula. *FP Essent* 2014 Apr;419:20–7.
17. Miller GV, Finan PJ. Flap advancement and core fistulectomy for complex rectal fistula. *Br J Surg* 1998 Jan;85(1):108–10.
18. Uribe N, Millán M, Minguez M, et al. Clinical and manometric results of endorectal advancement flaps for complex anal fistula. *Int J Colorectal Dis* 2007 Mar;22(3):259–64.
19. Schouten WR, Zimmerman DD, Briel JW. Transanal advancement flap repair of transsphincteric fistulas. *Dis Colon Rectum* 1999 Nov;42(11):1419–22; discussion 1422–3.
20. Malouf AJ, Buchanan GN, Carapeti EA, et al. A prospective audit of fistula-in-ano at St. Mark's hospital. *Colorectal Dis* 2002 Jan;4(1):13–19.
21. Nwaejike N, Gilliland R. Surgery for fistula-in-ano: an audit of practise of colorectal and general surgeons. *Colorectal Dis* 2007 Oct;9(8):749–53.