

ORIGINAL ARTICLE

PEER REVIEWED | OPEN ACCESS

Percutaneous spiral looped needle for peritoneal closure in laparoscopic transabdominal preperitoneal inguinal hernia repair

Ahmed E. Lasheen, Mohamed Abdelhamid, Taha Baiomy, Islam Ibrahim, Hassan Awad, Hassan Ashour, Nadia Ismail

ABSTRACT

Aims: Transabdominal preperitoneal (TAPP) entails the development of peritoneal flaps in order to reduce hernia sac and create a preperitoneal space in which mesh fixed. After mesh fixation at preperitoneal space, the peritoneal defect must be closed well to prevent mesh contact with the abdominal viscera and internal herniation with risk of possible complications. The peritoneal defect was closed by new spiral looped needle percutaneous in this study. **Methods:** This study included 47 patients suffering from inguinal hernias (27 indirect, 13 direct, 5 bilateral indirect types, 2 recurrent unilateral inguinal hernia after open hernia repair). This patients group subjected to transabdominal preperitoneal laparoscopic inguinal hernia repair from April 2015 through August 2016. The peritoneal defect closure in TAPP was done by spiral looped needle which passing to peritoneal cavity directly through abdominal wall. The outcome for this patients group was followed-up for period ranged from 5–23 months (mean 18 months). **Results:** The mean ages of patients group was 49 years (ranged from 23–67 years). The peritoneal defect closure time with our method ranged from 5–10 minutes

(mean 7.7 minutes). During the period of follow-up no intestinal obstruction or chronic pain or mesh migration were recorded. **Conclusion:** Using spiral looped needle for peritoneal defect closure during TAPP associated with good results and free of intraoperative and postoperative complications. Our technique is easy to learning and no need for much laparoscopic experience.

Keywords: Laparoscopic hernia repair, Peritoneal closure, Spiral needle

How to cite this article

Lasheen AE, Abdelhamid M, Baiomy T, Ibrahim I, Awad H, Ashour H, Ismail N. Percutaneous spiral looped needle for peritoneal closure in laparoscopic transabdominal preperitoneal inguinal hernia repair. Edorium J Surg 2017;4:8–13.

Article ID: 100018S05LA2017

doi:10.5348/S05-2017-18-OA-2

Ahmed E. Lasheen¹, Mohamed Abdelhamid¹, Taha Baiomy¹, Islam Ibrahim¹, Hassan Awad¹, Hassan Ashour¹, Nadia Ismail¹

Affiliations: ¹Laparoscopic & General Surgical Department, Faculty of medicine, Zagazig University, Egypt.

Corresponding Author: Ahmed E Lasheen, MD, General and Laparoscopic Surgery Department, Zagazig University Hospital, Zagazig City, Egypt; Email: lasheenahmed@yahoo.com

Received: 25 January 2017

Accepted: 28 March 2017

Published: 25 April 2017

INTRODUCTION

Inguinal hernia repair is one of the most common procedures performed in the world, in 1991 Corbitt first reported the technique of laparoscopic herniorrhaphy [1, 2]. The most common endoscopic techniques are transabdominal preperitoneal (TAPP) and totally extraperitoneal (TEP) approaches. TAPP is common surgical procedure for groin hernia repair in adults, especially for bilateral and recurrent inguinal hernias after open repair [3]. TAPP laparoscopic groin hernia

repair is regularly performed, and entails development of peritoneal flaps to reach the preperitoneal plane making space and reducing the hernia sac. After mesh fixation in its position, the peritoneal defect must be closed well to isolate the mesh from exposure to abdominal viscera reducing adhesion and prevent internal herniation through the defect to preperitoneal space [4]. The peritoneal defect closure is represented essential step in TAPP procedure, which tried by many procedures as suturing using laparoscopic needle holder, tacks, staples and glue [5–7]. But until now, not reached the suitable procedure for peritoneal defect closure in TAPP procedure [8]. This study offers novel technique to close peritoneal defect during TAPP procedure.

MATERIALS AND METHODS

This study was done from April 2015 through August 2016 in General and Laparoscopic Surgery Department, Zagazig University Hospital, Egypt. Forty-seven patients were included in this article. This research was discussed and approved from ethical committee of Zagazig University at January 2015. All information about the procedure was discussed with all patients, and gave writing consent for inclusion of their data in this study. The age of the patients ranged from 23–67 years (mean, 49 years).

Surgical technique: Under general anesthesia, TAPP procedure was used in this patients group. After pneumoperitoneum, the preperitoneal space was reached through peritoneal incision above the level of hernia defect. The hernia sac was dissected and reduced with forming good preperitoneal space. The dimensions of suitable mesh size were measured to cover all hernia defects with 5 cm overlap [9]. The suitable mesh (polypropylene mesh) go to preperitoneal space, where was fixed in its position using Glubran 2 (Gem srl, Viareggio, Italy). The peritoneum defect was closed using Vicryl No. 0 or 2/0 by helping spiral looped needle through the abdominal wall. The spiral looped needle was prepared by corresponding author for this study. This needle, its length is ranged from 25–30 cm, and its proximal end sharp and has large loop just after its tip. The proximal end is coiled in multiple rotations (ranged from 2–3) and the distance between each rotation about 1 cm. Follow, the proximal end the needle shaft which is straight and about 25 cm its length. The needle has small handle to direct and rotate the needle tip. The needle advances when the needle handle rotated with clockwise direction and withdrawn when rotated at anticlockwise direction (Figure 1A-F). The needle is passed at near and parallel point to peritoneal incision through the abdominal wall to peritoneal cavity by clockwise rotation with slight pushing of needle handle. The needle tip advances through the abdominal cavity and passes though the peritoneal flaps from one end to other end also by clockwise rotation slight pushing of needle handle (Figure 2). Then, the thread (Vicryl

No. 0 or 2/0) is loaded in the loop and the needle with thread end withdrawn by anticlockwise rotation with slight traction (Figure 3). When the needle tip with loop came out of peritoneal defect, the thread end is detached from the loop (Figure 4). The both thread ends were tied producing complete peritoneal closure (Figure 5). The pneumoperitoneum was emptied under direct viewing with the laparoscope and external pressure was applied

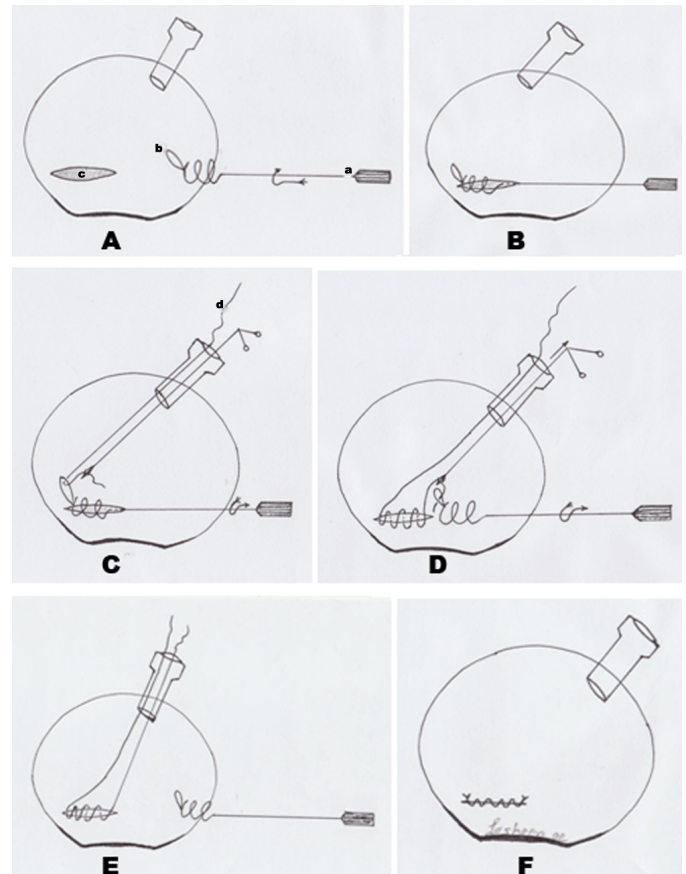


Figure 1: (A): a. Spiral looped needle. b Large looped at needle tip. c. Peritoneal defect with mesh fixed at preperitoneal space. The needle is passed through the abdominal wall at near and parallel point to peritoneal incision to peritoneal cavity by clockwise rotation with slight pushing of needle handle. (B) The needle tip advances through the abdominal cavity and passes through the peritoneal flaps from one end to other end also by clockwise rotation with slight pushing of needle handle. (C) d. The thread is Vicryl No. 0 or 2/0. The thread is loaded in the loop of needle by using laparoscopic forceps through working port. (D) The needle loop with thread end inside was withdrawn by anticlockwise rotation with slight traction of needle handle. When the needle tip with loop came out of peritoneal defect, the thread end is detached from the loop by using laparoscopic forceps. (E) The two ends of suture came out through working port. The spiral looped needle was removed from peritoneal cavity through abdominal wall by anticlockwise rotation with slight traction of needle handle. (F) The suture ends were tied extracorporeal or intracorporeal to produce good closure of peritoneal defect isolating the mesh completely from abdominal viscera. During suturing, the gas pressure must be lowering with external compression on inguinal area to allow gas which present in preperitoneal space to come out.

to the inguinal region. The follow-up period ranged from 5–23 months (mean 18 months). The intraoperative and postoperative complications were recorded.

RESULTS

Forty-seven patients suffering from inguinal hernias were included in this study (27 indirect, 13 direct, 5 bilateral indirect types, 2 recurrent unilateral

inguinal hernia after open hernia repair). The mean age was 49 years (range 23–67 years), mean BMI was 25.1 (range 18.7–30.3) and mean operative time was 90 minutes (range 70–110 minutes). The mean time to close the peritoneal defect by this technique was 7.7 minutes (range 5–10 minutes) (Table 1). The learning curve is short, the time to close peritoneal defect becomes less with more using our technique and more easy. The needle tip must be going through the abdominal wall at parallel plane to peritoneal incision plane to make procedure easy. Thirty-nine patients (83%) returned to their usual activities in one week and eight patients (17%) required up two weeks. Seven patients (15%) experienced mild inguinal pain for three weeks. Some precautions must be taken during our procedure for peritoneal defect closure, firstly lowering the intra-peritoneal pressure and secondly external compression on the inguinal area to allow the gas come out of preperitoneal space before tying

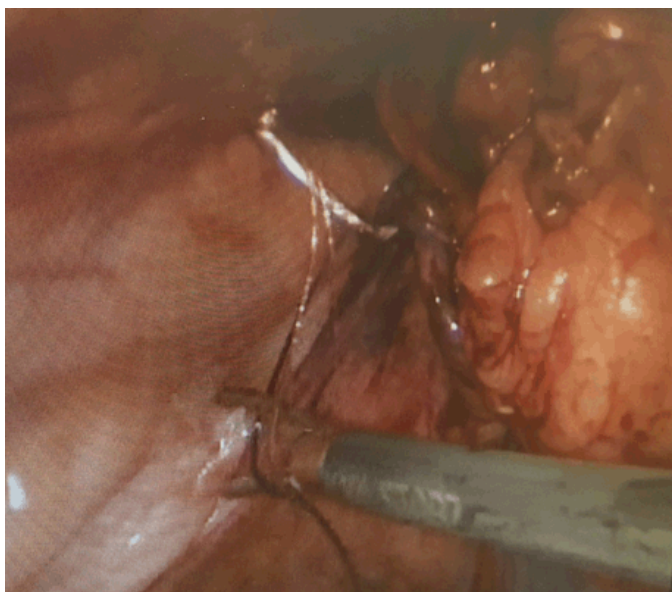


Figure 2: The needle tip advances through the abdominal cavity and passes through the peritoneal flaps from one end to other end also by clockwise rotation with slight pushing of needle handle. Then, the thread (Vicryl No. 0) is loaded in the loop by using laparoscopic forceps.

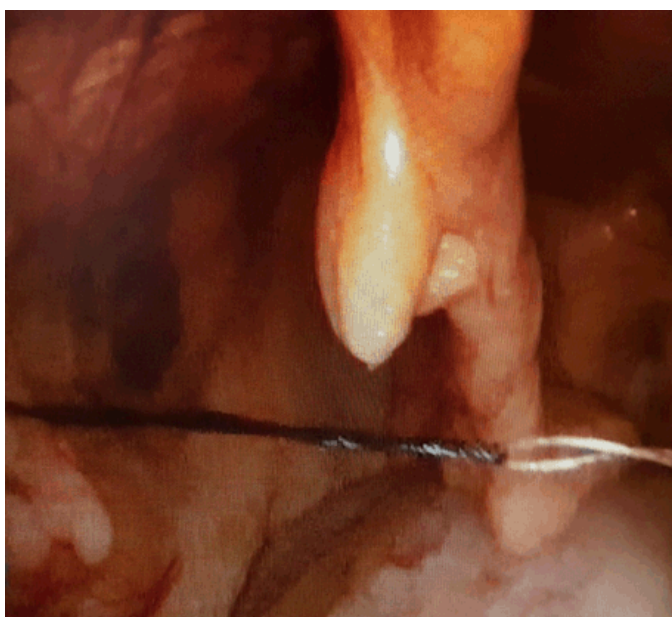

Figure 3: The needle with thread end inside the loop was withdrawn with anticlockwise rotation. When the needle tip with loop came out of peritoneal defect, the thread end is detached from the loop by using laparoscopic forceps.

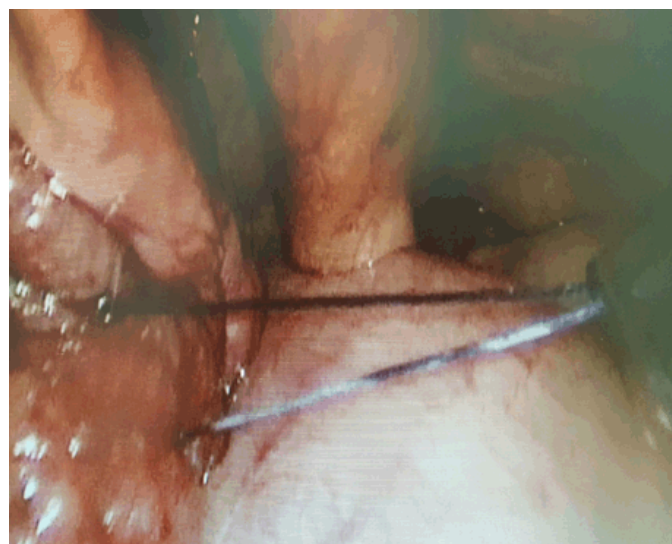

Figure 4: The two ends of thread were coming out of peritoneal cavity through the working port.

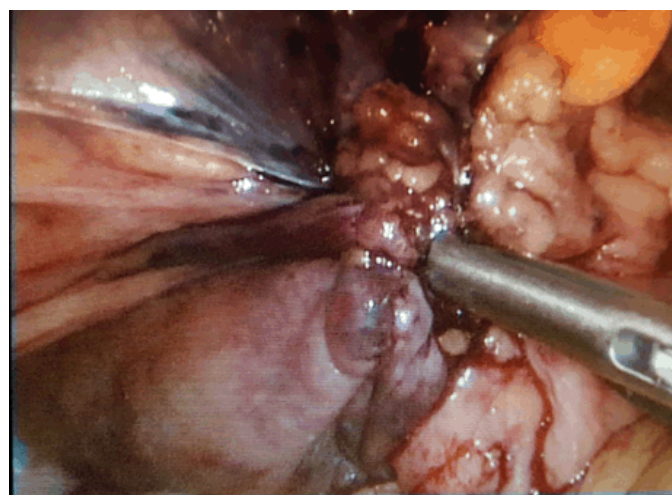


Figure 5: The stitch was tied extracorporeally producing complete closure of peritoneal defect.

Table 1: Patients data, and our technique data.

Patients number	Hernia type	Peritoneal incision length	Mean defect closure time	Mean age	Mean operative time	Mean BMI
47 patients	27 indirect, 13 direct, 5 bilateral indirect types, 2 recurrent unilateral inguinal hernia after open hernia repair	Ranged from 15–20 cm	7.7 minutes	49 years	90 minutes	25.1

the thread ends. The suture was tied extracorporeal or intracorporeal. The reports of this patients group were no intestinal colic or obstruction, no recurrence of hernia or chronic pain at the site of operation.

DISCUSSION

Although both the transabdominal preperitoneal and total extraperitoneal approaches to laparoscopic herniorrhaphy have acceptable for repair of inguinal hernia and have all advantages of minimally invasive surgery. TAPP laparoscopic groin hernia repair is more common because easier, a better view of the anatomy, shortening the learning curve, and can examine all abdominal contents [10, 11]. These procedures are associated with many complications which related to lack of thorough knowledge of surgical anatomy of pelvis or improper steps of technique [12, 13]. The complications rates ranged from 5% to 13% after laparoscopic hernia repair, but the complications definition differs widely among studies [14–17]. The peritoneum incision was made just above the level of hernia defect and extended from the medial umbilical ligament to anterior superior iliac spine to create good preperitoneal space. Allowing optimal mesh to be covered all hernias defects with 5 cm overlapping from all directions. But, this produced big peritoneal defect [18]. One of important step of TAPP procedure is closure of peritoneal defect after placing of mesh in preperitoneal space to isolate the mesh from contact with abdominal viscera preventing intestinal adhesion and internal herniation with their complications. Good closure of peritoneal flaps represented one of difficulties [19]. The methods for peritoneal defect closure were classified to mechanical methods as tickers, clips and staples which may be associated with risk of nerve injuries, incomplete closure, laceration of peritoneal flaps, ticks site herniation [20–22]. Recently, absorbable clips were developed for peritoneal defect closure during TAPP procedure but difficult in its application and with risk of incomplete closure [23]. Secondly, non-mechanical methods were used in peritoneal closure as sutures and glue substance. Some researches were reported that peritoneum closed with a running suture reducing the bowel and internal herniation to 0.8% to 0.1%. Using the laparoscopic needle holder or automatic devices to apply suture are complicated, required special port and long experience [24]. After successful using braded thread in plastic and reconstructive surgery, it's using was extended to close

peritoneal defect with advantages of self-anchoring and knotless sutures [18]. Disadvantages are incomplete closure because the thread can be cutting through thin peritoneal flaps with frequent internal herniation. Also, one of big problem of using braded thread in surgery that the barbs have affinity to move forward. So, the ends of braded suture must be covered and fixed by good amount of tissue. If not do like this, the uncovered parts of braded suture will be penetrated the near organs like intestine producing serious complications as peritonitis and intestinal obstruction [25–27]. With using our spiral looped needle to close peritoneal defect passes percutaneously through the abdominal wall at nearest and parallel to peritoneal incision to make procedure easy. The intra-peritoneal pressure must be decreased with the needle tip passing from upper to lower peritoneal flaps by helping of laparoscopic forceps with clockwise rotation and slightly pushing of needle handle. So this procedure does not needing to more port or much instrumentations. The manipulation of this spiral looped needle is easy by beginner laparoscopic surgeon.

CONCLUSION

The using novel spiral looped needle for peritoneal closure during transabdominal preperitoneal procedure is associated with good results in form complete closure and free of intraoperative and postoperative complications. Our technique has shortening learning curve.

Author Contributions

Ahmed E. Lasheen – Substantial contributions to conception and design, Acquisition of data, Analysis and interpretation of data, Drafting the article, revising it critically for important intellectual content, Final approval of the version to be published

Mohamed Abdelhamid – Analysis and interpretation of data, Revising it critically for important intellectual content, Final approval of the version to be published

Taha Baiomy – Analysis and interpretation of data, Revising it critically for important intellectual content, Final approval of the version to be published

Islam Ibrahim – Analysis and interpretation of data, Revising it critically for important intellectual content, Final approval of the version to be published

Hassan Awad – Analysis and interpretation of data,
Revising it critically for important intellectual content,
Final approval of the version to be published

Hassan Ashour – Analysis and interpretation of data,
Revising it critically for important intellectual content,
Final approval of the version to be published

Nadia Ismail – Analysis and interpretation of data,
Revising it critically for important intellectual content,
Final approval of the version to be published

Guarantor

The corresponding author is the guarantor of submission.

Conflict of Interest

Authors declare no conflict of interest.

Copyright

© 2017 Ahmed E. Lasheen et al. This article is distributed under the terms of Creative Commons Attribution License which permits unrestricted use, distribution and reproduction in any medium provided the original author(s) and original publisher are properly credited. Please see the copyright policy on the journal website for more information.

REFERENCES

- Corbitt JD Jr. Laparoscopic herniorrhaphy. *Surg Laparosc Endosc* 1991 Mar;1(1):23–5.
- Masukawa K, Wilson SE. Is postoperative chronic pain syndrome higher with mesh repair of inguinal hernia? *Am Surg* 2010 Oct;76(10):1115–8.
- Mahon D, Decadt B, Rhodes M. Prospective randomized trial of laparoscopic (transabdominal preperitoneal) vs open (mesh) repair for bilateral and recurrent inguinal hernia. *Surg Endosc* 2003 Sep;17(9):1386–90.
- McKay R. Preperitoneal herniation and bowel obstruction post laparoscopic inguinal hernia repair: Case report and review of the literature. *Hernia* 2008 Oct;12(5):535–7.
- Oguz H, Karagulle E, Turk E, Moray G. Comparison of peritoneal closure techniques in laparoscopic transabdominal preperitoneal inguinal hernia repair: a prospective randomized study. *Hernia* 2015 Dec;19(6):879–85.
- Uchida K, Morimoto H, Tashiro H, Ohdan H, Yamamoto M. New suture: Tail clinch knot for transabdominal preperitoneal hernia repair. *Asian J Endosc Surg* 2015 Feb;8(1):98–9.
- Sharma D, Yadav K, Hazrah P, Borgharia S, Lal R, Thomas S. Prospective randomized trial comparing laparoscopic transabdominal preperitoneal (TAPP) and laparoscopic totally extra peritoneal (TEP) approach for bilateral inguinal hernias. *Int J Surg* 2015 Oct;22:110–7.
- Ross SW, Oommen B, Kim M, Walters AL, Augenstein VA, Heniford BT. Tacks, staples, or suture: method of peritoneal closure in laparoscopic transabdominal preperitoneal inguinal hernia repair effects early quality of life. *Surg Endosc* 2015 Jul;29(7):1686–93.
- Lasheen AE, Safwat K, Morsy M, Allam Z, Awad W. Modified transabdominal external needle for mesh size estimation in laparoscopic hernia repair. *Int J Surg* 2014 Oct;12(10):1074–6.
- Novitsky YW, Czerniach DR, Kercher KW. Advantages of laparoscopic transabdominal preperitoneal herniorrhaphy in the evaluation and management of inguinal hernias. *Am J Surg* 2007 Apr;193(4):466–70.
- Anadol ZA, Ersoy E, Taneri F, Tekin E. Outcome and cost comparison of laparoscopic transabdominal preperitoneal hernia repair versus Open Lichtenstein technique. *J Laparoendosc Adv Surg Tech A* 2004 Jun;14(3):159–63.
- Xue TM, Tao LD, Zhang J, Zhang PJ. Mesh erosion causes small bowel obstruction: A rare complication of laparoscopic inguinal hernia repair: Case description and review of literature. *Hepatogastroenterology* 2015 Jan–Feb;62(137):55–8.
- Kosai N, Sutton PA, Evans J, Varghese J. Laparoscopic preperitoneal mesh repair using a novel self-adhesive mesh. *J Minim Access Surg* 2011 Jul;7(3):192–4.
- Muschalla F, Schwarz J, Bittner R. Effectivity of laparoscopic inguinal hernia repair (TAPP) in daily clinical practice: Early and long-term result. *Surg Endosc* 2016 Nov;30(11):4985–94.
- Samra NS, Ballard DH, Doumit DF, Griffen FD. Repair of large sliding inguinal hernias. *Am Surg* 2015 Dec;81(12):1204–8.
- Payne J. Complications of laparoscopic inguinal herniorrhaphy. *Semin Laparosc Surg* 1997;4(3):166–81.
- Miguel PR, Reusch M, daRosa AL, Carlos JR. Laparoscopic hernia repair–complications. *JSLs* 1998 Jan–Mar;2(1):35–40.
- Takayama S, Nakai N, Shiozaki M, Ogawa R, Sakamoto M, Takeyama H. Use of barbed suture for peritoneal closure in transabdominal preperitoneal hernia repair. *World J Gastrointest Surg* 2012 Jul 27;4(7):177–9.
- Köhler G, Mayer F, Lechner M, Bittner R. Small bowel obstruction after TAPP repair caused by a self-anchoring barbed suture device for peritoneal closure: Case report and review of the literature. *Hernia* 2015 Jun;19(3):389–94.
- Tolver MA, Rosenberg J, Juul P, Bisgaard T. Randomized clinical trial of fibrin glue versus tacked fixation in laparoscopic groin hernia repair. *Surg Endosc* 2013 Aug;27(8):2727–33.
- Lovisetto F, Zonta S, Rota E, et al. Use of human fibrin glue (Tissucol) versus staples for mesh fixation in laparoscopic transabdominal preperitoneal hernioplasty: A prospective, randomized study. *Ann Surg* 2007 Feb;245(2):222–31.
- LeBlanc KA. Tack hernia: A new entity. *JSLs* 2003 Oct–Dec;7(4):383–7.
- Bittner R, Leibl BJ, Jäger C, Kraft B, Ulrich M, Schwarz J. TAPP - Stuttgart technique and result of a large single center series. *J Minim Access Surg* 2006 Sep;2(3):155–9.
- Kapiris SA, Brough WA, Royston CM, O'Boyle C, Sedman PC. Laparoscopic transabdominal preperitoneal (TAPP) hernia repair. A 7-year two-center experience in 3017 patients. *Surg Endosc* 2001 Sep;15(9):972–5.

25. Burchett MA, Mattar SG, McKenna DT. Iatrogenic intestinal and mesenteric injuries with small bowel volvulus following use of barbed suture during laparoscopic myomectomy. *J Laparoendosc Adv Surg Tech A* 2013 Jul;23(7):632–4.
26. Buchs NC, Ostermann S, Hauser J, Roche B, Iselin CE, Morel P. Intestinal obstruction following use of laparoscopic barbed suture: A new complication with new material? *Minim Invasive Ther Allied Technol* 2012 Sep;21(5):369–71.
27. Nemecek E, Negrin L, Beran C, Nemecek R, Hollinsky C. The application of the V-Loc closure device for gastrointestinal sutures: A preliminary study. *Surg Endosc* 2013 Oct;27(10):3830–4.

Access full text article on
other devices



Access PDF of article on
other devices

